

RECONSTRUCTION OF THE ZYGOMATIC BONE WITH SMARTBONE®: CASE REPORT

F. GRECCHI¹, G. PERALE^{2,3}, V. CANDOTTO⁴, A. BUSATO⁵, M. PASCALI⁶ and F. CARINCI⁴

¹Department of Maxillofacial Surgery, Galeazzi Hospital, Milan, Italy; ²Industrie Biomediche Insabri SA, Mezzovico-Vira, Switzerland; ³Department of innovative Technologies, University for Applied Science and Art of Southern Switzerland, Manno, Switzerland; ⁴Department of Morphology, Surgery and Experimental Medicine, University of Ferrara, Ferrara, Italy; ⁵Private Practitioner, Milan, Italy; ⁶Department of Biomedicine and Prevention, University of Tor Vergata, Roma, Italy

The repair of complex craniofacial bone defects is challenging and a successful result depends on the defect size, the quality of the soft tissue covering the defect and the choice of reconstructive method. Autologous bone grafts are the gold standard for bone replacement. Tissue engineered constructs are temporary substitutes developed to treat damaged or lost tissue. Recent advances in materials science have provided an abundance of innovations, underlining the increasing importance of polymer in this field. The Galeazzi Orthopedical institute of Milan received a Serbian soldier who reported a deep wound, due to the explosion of a grenade, during former-Yugoslavia's war. His left cheekbone was completely lost, together with the floor of the left eye. SmartBone® technology allowed the realization of custom-made grafts which perfectly fitted the bone defect thanks to mechanical strength, also at small thicknesses, and the ability to be shaped without powder formation or unpredicted fractures. Tissue engineering approaches to regeneration utilize 3-dimensional (3D) biomaterial matrices that interact favorably with cells. The potential benefits of using a tissue engineering approach include reduced donor site morbidity, shortened operative time, decreased technical difficulty of the repair, ability to closely mimic the *in vivo* microenvironment in an attempt to recapitulate normal craniofacial development: this 36-month case study allowed to prove that SmartBone® custom-made bone grafts are an effective solution, gathering such benefits and being available now for daily routine.

The repair of complex craniofacial bone defects is challenging, and a successful result depends on the defect size, the quality of the soft tissue covering the defect, and the choice of reconstructive method. The complex craniofacial skeleton is involved with various specific functions, such as protection of the brain and optic tracts, breathing, mastication, speech, and hearing. In addition to these functional requirements, the craniofacial unit is important for social acceptance and self-esteem (1). Autologous

bone grafts began to be considered as the gold standard for bone replacement, mainly because they offer minimum immunological rejection, complete histocompatibility and provide the best osteoconductive (a matrix which provides a scaffold for bone in growth), osteogenic (living bone cells) and osteo-inductive (growth factors) properties. Autologous cancellous bone graft has been considered more osteogenetic as compared to cortical bone graft because the presence of spaces within

Key words: alloplastic implants, bone reconstruction, injury, SmartBone®

Mailing address: Prof. Francesco Carinci,
Department of Morphology,
Surgery and Experimental Medicine,
University of Ferrara, Luigi Borsari 46, Ferrara, Italy
Tel.: +39 0532 455874
e-mail: crc@unife.it
Web: www.carinci.org

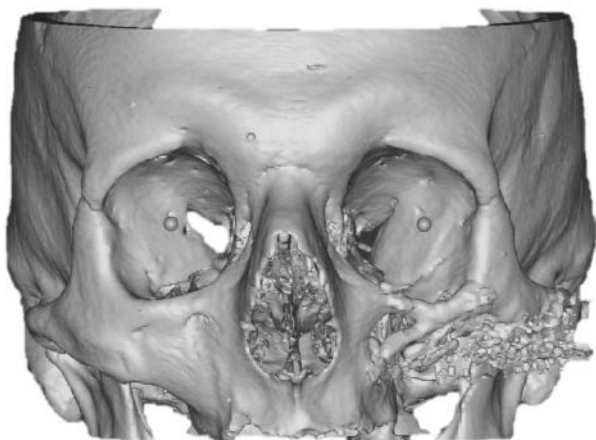


Fig. 1. Pre-operative CT-scan of the patient.

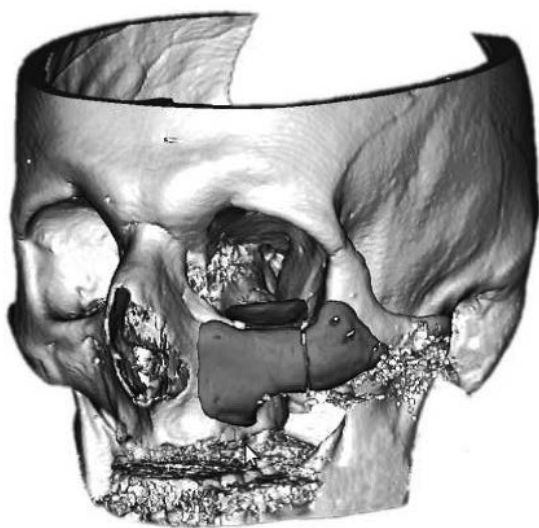


Fig. 2. 3D CT reconstruction with bone graft modelling (software).

their structure allows the diffusion of nutrients and limited revascularization by micro anastomosis of its circulating vessels (2). Bone can also be harvested from sites distant to the primary area of concern: it is usually harvested from the iliac crest (but the proximal tibia, distal radius, calvaria, calcaneus and mandibular jaw can also be used as donor sites). In selected surgical scenarios when the structural integrity of bone is compromised, also cortical auto-

grafts can be used for bone reconstruction and fibular auto-grafts have been used to replace defects in the forearm, and face (3). Harvesting of autologous bone tissue lengthens the surgical procedure, and is associated with risk of complications that include infection, blood loss, hematoma, nerve and urethral injury, fracture, pelvic instability, cosmetic disadvantages, postoperative pain, and morbidity and chronic pain at the donor site. Finally, the use of auto grafts is not recommended in elderly or pediatric patients or in patients with a malignancy or infectious disease (3).

Tissue engineered constructs are temporary substitutes developed to treat damaged or lost tissue. One key component of such constructs is represented by the so-called “scaffolds”, which are often developed to mimic the extra cellular matrix (ECM). As natural ECM contains biomolecules to support proper growth and function of cells, inclusion of these bio molecular cues have been shown to be necessary for proper cell growth and function in tissue engineering. Thus, effective tissue engineering scaffolds should provide such bio molecular cues. Bone defects are conventionally treated by replacement with bone grafts and synthetic bone filling materials. However, the tissue engineering approach, which stresses tissue regeneration rather than tissue replacement, has recently become popular. Porous scaffolds used in tissue engineering allow cells to attach, proliferate, differentiate and eventually become specific tissue(s). While scaffolds are expected to disappear after implantation *in vivo*, being progressively substituted by newly formed functional tissue, a certain level of mechanical strength is required for the scaffolds to withstand a certain level of physiological loading. The open porosity of the porous scaffolds is also important for the tissue development from cells, where cell culture medium and growth factors can be easily accessed through the open pores (4). For bone tissue engineering, the design of scaffolds should mimic the structure and properties of the bone extracellular matrices. Because bone consists of a porous composite of interpenetrating phases of hydroxyapatite and collagen, the scaffolds for bone regeneration should be similarly porous composites with interpenetrating ceramic and polymer phases. Porous hydroxyapatite/tricalcium phosphate (HA/TCP) composite was thought to be ideal, as it is known




Fig. 3. *SmartBone® blocks milled giving the shaped bone grafts.*

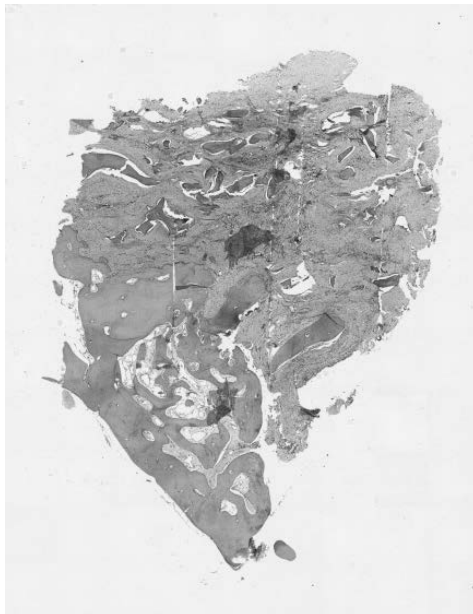

Fig. 4. *Histology of bone piece.*

for its excellent osteo-conductivity and, in some cases, even osteo-inductivity (5). On the other hand, poly(lactic-co-glycolic) acid (PLGA) polymer was first used as polymeric phase in synthetic devices, as it is an FDA-approved biodegradable polymer with some degree of ductility and good biocompatibility (6, 7), but clinical experience had proved not always satisfactory results. The next generation of orthopedic biomaterials is hence likely to involve

composites, which are tailored to meet a particular demand. Recent advances in materials science have provided an abundance of innovations, underling the increasing importance of polymer in this field. Currently, the poly(α -hydroxy acids), specifically poly(lactic acid) (PLA), poly(glycolic acid) PGA, poly(ϵ -caprolactone) PCL, and relative copolymers are the most widely used synthetic polymers in the tissue engineering field (8). These polymers degrade by hydrolysis into non-toxic, natural metabolites, which are eventually eliminated from the body in the form of carbon dioxide and water.

Case report

The Galeazzi Orthopedical Institute of Milan (Italy) received a case of a Serbian soldier who reported a deep wound, due to the explosion of a grenade, during former-Yugoslavia's war. His left cheekbone was completely lost and also the floor of the left eye. He was roughly reconstructed at the battle field hospital back then, with evident outcomes: a computed tomography (CT) (Fig. 1) provided the exact acquisition of bone scans, which can be put together into a computer-based 3D model (Fig. 2). The computer-based data processing allowed mirroring structures from the contralateral healthy side to fit the defect. This facilitated the design process, especially for the reconstruction of complex anatomical structures like the zygomatic bone and sphenoidal crest.

A two parallel ways approach was followed to design the custom made grafts: firstly the 3D casting of the patient skull bones in pre-operative conditions offered the advantage of being able to form very thinly tapered shapes, hence offering the surgeon a very precise 3D real model onto which manually shape the needed grafts (using Surgiplanner® platform, Ikon srl, Milan, Italy). Extreme precision may become even more important when constructing zygomatic bones or producing titanium space holders to promote guided tissue regeneration of skull defects. A software used for CAD/computer-aided manufacturing (CAM) in industrial engineering was needed for 3D geometric building of skull bones and then performed the individual graft design onto the real model: the surgeon removed from the model the bony fragments generated from the previous intervention and new substitutes were modelled with

wax onto the skull. Bone grafts were then scanned and edges and contours finished. Here the second pathway was followed, where virtual approach was then used to compare and contrast the resulting bone substitutes shows the virtual model with the bone grafts shaped by Plasty-CAD software (3DiEmme srl, Cantù, Italy): indeed, in this second approach, the computer based model served as the basis for the freeform-surfaces-design of grafts geometry and for fine tuning of grafts design. The stereolithographics files (.stl) were finally sent to the milling machine software and SmartBone® blocks were milled giving the shaped bone grafts, *i.e.* custom-made patient-specific bone grafts (Fig. 3), *a.k.a.* SmartBone® on Demand™.

Once manufactured and duly sterilized, bone grafts were sent into the operating theatre: the first surgical step consisted in creating an access to the bone tissue below using the scar of the previous operation. When the patient's healthy bones were highly visible, osteotomy guides were positioned. They defined the precise limits where to cut the autologous bone stump in order to have a perfect match with the bone substitute. Osteotomy guides were kept in position with fixation screws, because the precision in bone cutting has to be guaranteed in order to have a perfect match with the grafts. Intramedullary canalization was performed before grafting to stimulate osteo-induction. The positioning of bone substitutes according to reconstruction scheduled was performed and grafts were fixed with screws and two plates. Bone grafts were dipped into the patient's warm blood for some minutes prior to implantation in order to let them absorb as much blood as possible: this widely used surgical practice is based on the evidence that blood starts coagulating inside the graft and thus several growth factors and biochemical signalling molecules are released, finally enhancing and speeding up graft integration once placed into the target host site. Three of the four made bone grafts were placed while the fourth one, machined as a complementary component to be used only in case of need, was not: it was supposed indeed to be, eventually, in replacement of the side base of the ethmoidal bone in the event of this bone portion being broken during surgical field preparation. An event which did not take occur: surgeon ability to prepare the field by removing the old graft

allowed to preserve the native healthy ethmoidal bone segment at the nose side. The next step was to carry out surgical toilet: the surgeon refined the irregular healthy bone stumps according to the limits imposed by osteotomy guides. In the end a collagen membrane was opposed on the implants and then sutured points were performed. First checks were carried out on the patient immediately after surgery to control postoperatively that the bone substitutes were properly in place and that the symmetry of the face had been correctly restored: it was noticed that in correspondence of left cheekbone there was no longer an empty space below the soft tissue, but the zygomatic bone was noticeable. Also, eye alignment had been successfully restored. A second follow-up with CT was performed after nine months, showing a restored symmetry of the skull, which demonstrates a long-term efficacy of the whole process.

Finally, aesthetic surgery was performed 30 months after grafting to fill soft tissue volume of the new bone structure, hence ensuring a completely symmetric reconstruction outcome. During this revision surgery a fragment of zygomatic bone of about 1 cm was harvested and then sent to the Institute of Pathologic Anatomy of University of Milan (Italy). The histological report also stated: "Lamellar bone tissue architecture with irregular, altered by the presence of areas of densification from neo-apposition of new bone. Bone lamellae have multiple lines cementing also with occasional osteoclastic gaps uninhabited. Interlayer fibrosis and neo-vascularization with ecstatic vessels are also present" (Fig. 4).

DISCUSSION

Reconstruction of craniofacial defects requires a combination of function and aesthetic repair principles (9). A variety of techniques and restorative procedures have been described for this purpose, including autogenic or allogeneic bone grafting, as well as the use of alloplastic materials that can be molded during, or prior to, surgical reconstruction. Each of the possible options has advantages and disadvantages in its use (10).

Even though osseous tissue has the unique internal repair capacity to heal and remodel without scarring, there are several conditions, both congenital and

acquired, where bone replacement is needed.

Autologous grafting is the therapeutically obvious gold standard in reconstructive surgery owing to high immunocompatibility (10). However, this concept is bound by several constraints (e.g. requirement of secondary surgery, limited amount of tissue that can be harvested, increased risk of infection or recurrent pain) (11, 12). Allograft or xenograft grafting are optional treatments, but each process has its own disadvantages including the possibility of graft rejection by the immune system, risk of infections and transmission of donor pathogens (13). To overcome these problems, tissue engineering approaches are emerging as convenient alternatives to promote the regenerative ability of the host body. In this respect, several authors have proposed the use of belayed osteochondral constructs for the improved regeneration of cartilage defects (14, 15). Basically, this conceptual approach consists of developing a single 3D porous structure that combines a mechanical support resembling the subchondral bone (bone-like layer), while also providing a chondrogenic support at the top for the repairing of cartilage (cartilage-like layer) (16). Materials such as hydroxyapatite (HA) (17) and chitosan have been widely employed to develop suitable 3D supports for applications in tissue engineering of bone and cartilage, respectively.

More recent tissue engineering approaches to regeneration utilize 3-dimensional (3D) biomaterial matrices that interact favorably with cells (18, 19). The potential benefits of using a tissue engineering approach include reduced donor site morbidity, shortened operative time, decreased technical difficulty of the repair, and, most important, ability to closely mimic the *in vivo* microenvironment in an attempt to recapitulate normal craniofacial development (5).

In large craniofacial reconstruction procedures SmartBone® implants have proven to be effective, easy to handle and biocompatible, providing excellent final aesthetic and functional results. 3D reconstruction of the defect greatly assists in the diagnosis and surgical planning, allowing surgical time to be decreased. Custom-made SmartBone® on Demand™ grafts manufactured over real models, such as those described in this study, proved to be effective and feasible. In addition to features

inherent to SmartBone® implants, the feasibility of the on Demand™ technique and the access of this technology through the public health system are unique to this study.

Synthetic materials and combinations with naturally derived materials, as well as improved scaffold designs based on innovative processing techniques, are being continuously proposed to advance the capability of bone tissue scaffolds and SmartBone® custom-made bone grafts proved to be an effective solution, available now for daily routine.

REFERENCES

1. Adams SS, Humphries RG, Mason CG. The relationship between development of ultraviolet erythema and release of prostaglandins in guinea pig skin. *Agents Actions* 1981; 11(5):473-476.
2. Nandi SK, Roy S, Mukherjee P, Kundu B, De DK, Basu D. Orthopaedic applications of bone graft & graft substitutes: a review. *Indian J Med Res* 2010; 132:15-30.
3. Van Lieshout EM, Van Kralingen GH, El-Massoudi Y, Weinans H, Patka P. Microstructure and biomechanical characteristics of bone substitutes for trauma and orthopaedic surgery. *BMC Musculoskelet Disord* 2011; 12:34.
4. Cordonnier T, Langonne A, Sohier J, Layrolle P, Rosset P, Sensebe L, Deschaseaux F. Consistent osteoblastic differentiation of human mesenchymal stem cells with bone morphogenetic protein 4 and low serum. *Tissue Eng Part C Methods* 2011; 17(3):249-259.
5. Arinzech TL, Tran T, McAlary J, Daculsi G. A comparative study of biphasic calcium phosphate ceramics for human mesenchymal stem-cell-induced bone formation. *Biomaterials* 2005; 26(17):3631-3638.
6. Chastain SR, Kundu AK, Dhar S, Calvert JW, Putnam AJ. Adhesion of mesenchymal stem cells to polymer scaffolds occurs via distinct ECM ligands and controls their osteogenic differentiation. *J Biomed Mater Res A* 2006; 78(1):73-85.
7. Xin X, Hussain M, Mao JJ. Continuing differentiation of human mesenchymal stem cells and induced chondrogenic and osteogenic lineages in electrospun PLGA nanofiber scaffold. *Biomaterials* 2007;

- 28(2):316-325.
8. Louis PJ. Bone grafting the mandible. *Oral Maxillofac Surg Clin North Am* 2011; 23(2):209-227.
 9. Brydone AS, Meek D, Maclaine S. Bone grafting, orthopaedic biomaterials, and the clinical need for bone engineering. *Proc Inst Mech Eng H* 2010; 224(12):1329-1343.
 10. Reichert JC, Saifzadeh S, Wullschlegler ME, et al. The challenge of establishing preclinical models for segmental bone defect research. *Biomaterials* 2009; 30(12):2149-2163.
 11. Younger EM, Chapman MW. Morbidity at bone graft donor sites. *J Orthop Trauma* 1989; 3(3):192-195.
 12. Arosarena OA, Madsen M, Haug R. Special considerations with floor of mouth and tongue cancer. *Oral Maxillofac Surg Clin North Am* 2006; 18(4):521-531.
 13. Kumar A, Eckman JR, Wick TM. Inhibition of plasma-mediated adherence of sickle erythrocytes to microvascular endothelium by conformationally constrained RGD-containing peptides. *Am J Hematol* 1996; 53(2):92-98.
 14. Schaefer D, Martin I, Jundt G, Seidel J, Heberer M, Grodzinsky A, Bergin I, Vunjak-Novakovic G, Freed LE. Tissue-engineered composites for the repair of large osteochondral defects. *Arthritis Rheum* 2002; 46(9):2524-2534.
 15. Gao J, Dennis JE, Solchaga LA, Goldberg VM, Caplan AI. Repair of osteochondral defect with tissue-engineered two-phase composite material of injectable calcium phosphate and hyaluronan sponge. *Tissue Eng* 2002; 8(5):827-837.
 16. Gronthos S. Reconstruction of human mandible by tissue engineering. *Lancet* 2004; 364(9436):735-736.
 17. Schek RM, Taboas JM, Segvich SJ, Hollister SJ, Krebsbach PH. Engineered osteochondral grafts using biphasic composite solid free-form fabricated scaffolds. *Tissue Eng* 2004; 10(9-10):1376-1385.
 18. Kotobuki N, Ioku K, Kawagoe D, Fujimori H, Goto S, Ohgushi H. Observation of osteogenic differentiation cascade of living mesenchymal stem cells on transparent hydroxyapatite ceramics. *Biomaterials* 2005; 26(7):779-785.
 19. Kasten P, Vogel J, Luginbuhl R, et al. Ectopic bone formation associated with mesenchymal stem cells in a resorbable calcium deficient hydroxyapatite carrier. *Biomaterials* 2005; 26(29):5879-5889.